

Fennel, Carob, Rosemary Extracts as Anti-Inflammatory Activity Functions on Formalin Induced Paw Edema in Albino Rats

¹Nasra, A. Abd-Elhak, ^{*2}Hanaa, S. M. Abd El-Rahman & ²Mahmoud, A.M. Saleh

¹Experimental Kitchen Research Unit, Food Technology Research Institute, Agricultural Research Center, Giza, Egypt

²Department of Special Food and Nutrition, Food Technology Research Institute, Agricultural Research Center, Giza, Egypt

Original Article

Article information

Received 06/01/2024

Revised 23/01/2024

Accepted 05/02/2024

Published 10/02/2024

Available online

01/03/2024

Keywords:

Anti-inflammatory - Anti-oxidant Activities- carob-fennel – rosemary

ABSTRACT

Inflammation and oxidative stress are features of many degenerative illnesses. In this study, the anti-inflammatory and antioxidant effects of fennel fruits (*Foeniculum vulgare*), carob (*Ceratonia siliqua* L), and rosemary (*Rosmarinus officinalis* L) aqueous extracts were investigated in vivo. Two models of formalin-induced paw edema were used to investigate the anti-inflammatory impact. The rat was given a formalin injection to cause an inflammatory process resulting in edema in the right leg. Formalin at 2.5% and 10% concentrations resulted in rat paw edema. In the anti-inflammatory study, Group 1: Normal control; no induced inflammation. Positive control (group 2) was given formalin. Rats were administered 200 and 400 mg/kg b.w. of fennel extract to groups 3 and 4. Rats given formalin received carob extracts at dosages of 400 and 800 mg/kg. in Groups 5 and 6. Groups 7, 8: Formalin-treated rats were given 200 mg/kg b.w. and 400 mg/kg. of rosemary extracts. Group 9 includes rats administered formalin plus indomethacin at a dose of 10 mg/kg. In the two experimental formalin models (A and B), aqueous extracts and the standard drug were administered orally through a gastric tube 30 minutes after the formalin injection in the right hind of the rat paw. Following the 15-day trial period, blood and tissue samples were taken, and histopathological and biochemical parameter analyses were done. According to research, these plant aqueous extracts effectively reduce inflammation in rat paw edema caused by formalin.

1. Introduction

A living, vascularized tissue experiences inflammation in response to injury. Conventional or synthetic medications used to treat inflammatory disorders are insufficient and can occasionally have detrimental side effects, according to (Sumathi and Anuradha 2018). Plant-based medications are well known for their reliability, accessibility, and affordability (Iwu et al., 1999). In Egypt and other industrialized nations, the use of medicinal plants for health purposes dates back thousands of years and is being practiced by doctors today. According to (Guilled and Manzanons 1996), fennel is an aromatic edible plant whose fruits are used in savory recipes, sauces, liqueurs, confections, and other foods. Fresh fennel salads are made with the swollen bases because of

their distinct and preferred flavor and perfume. According to (Barros et al., 2009), fennel (*Foeniculum vulgare*) fruits, leaves, and fruits are a possible source of natural antioxidants. The Greek word "Kera," which refers to the keratomorphic shape of the fruit, and the Latin word "siliqua," which describes the hardness and shape of the pods, are combined to form the scientific name of the carob tree, *Ceratonia siliqua* L. Most Mediterranean nations plant carob trees, primarily in arid and temperate climates. According to (Goulas et al., 2016), 160,000 tons of carob are produced worldwide each year. Depending on the variety, the plant *Foeniculum vulgare* can be an annual, biennial, or perennial. It is a well-known umbelliferous plant. The fruits stems, and leaves can all be eaten.

According to (Cosge et al., 2008), fennel is the ripe fruit, also known as the seed, of the *Foeniculum vulgare* plant. Fennel is sometimes used as a diuretic and may be a useful diuretic as well as a possible medication to treat hypertension. According to (Choie and Hwang 2004), fennel fruits also have a hypotensive effect, antispasmodic properties, anti-hirsutism, hepatoprotective properties, anti-inflammatory properties, and antidementia properties. One of the Lamiaceae family's most economically significant species is rosemary (*Rosmarinus officinalis* L.). Due to its commercial uses in the food and fragrance industries as well as its culinary, medical, and commercial uses, the plant, originally from the Mediterranean region, is now widely diffused around the world (Habtemariam, 2016). According to (Hamidpour et al., 2017), rosemary has demonstrated significant promise as a natural food preservative and medicinal agent for the treatment of numerous ailments. Rosemary has been shown to provide medical benefits that include anticancer (Cheung and Tai 2007), antidiabetic (Bakirel et al., 2008), anti-inflammatory, and antioxidant properties (Laura et al. 2010). Finding the appropriate extract concentrations from fennel fruits, rosemary leaves, and carob pods for treating edema is the goal of the current study.

2. Materials and Methods

Chemicals: The chemicals used in the study were of analytical grade and procured from Sigma Chemical Co., USA. All biochemical assay kits were purchased from Randox Laboratories Ltd., Diamond Road, Crumlin, Co. Antrim, United Kingdom, BT294QY.

Plant Material

Fennel fruits (*Foeniculum vulgare*), carob pods (*Ceratonia siliqua* L.), and rosemary (*Rosmarinus officinalis* L.) leaves were obtained from Haraz market for herbs and medicinal plants in Cairo, Egypt.

Preparation of plant extracts

The extraction process was carried out in the approved manner by (Maxwell et al., 2015). The fennel fruits, carob pods, and rosemary leaves were

individually ground in a mill. For this, fifty grams of ground plant were placed in a conical flask (2000 ml capacity) and extracted by adding 500 ml of pre-boiled water with shaking (120 rpm) for 24 hours at room temperature (28°C ±1). Plant debris was removed by filtration through gauze, and the collected extract was filtrated by passing through filter paper (Whatman no. 1). The filtrate was dried in an oven at 40°C until concentrated and then saved in dark, closed bottles in the deep (-18 °C) freezer until use.

Antioxidant activity of fennel fruits, carob pods, and rosemary leaves powder and their extracts

According to (Thaipong et al., 2006), the radical scavenging activity of fennel fruits, carob pods, and rosemary leaves powder and their extracts was investigated using 2,2-diphenyl-1-picrylhydrazyl (DPPH). Each sample (500 µl) was added to a methanolic DPPH radical solution (1 ml) (the final concentration of DPPH was 0.2 mM). The mixture was briskly agitated and allowed to rest for 30 minutes at room temperature. At 517 nm, the absorbance of the solution was spectrophotometrically determined using UV (67 Series), Jenway, UK. Antioxidant activity was calculated as a percentage inhibition using the formula:

Antioxidant activity (%) = [(Absorbance of control - Absorbance of sample) / Absorbance of control] × 100

Total phenolics of fennel fruits, carob pods, and rosemary leaves powder and their extract

The total phenolic component content of fennel fruits, carob pods, and rosemary leaves powder and their extracts were calorimetrically measured using the Folin-Ciocalteu reagent (as mg gallic acid/g sample), as according to (Singleton et al., 1999).

Total flavonoids of fennel fruits, carob pods, and rosemary leaves powder and their extracts

Total flavonoid content was determined using aluminum chloride (AlCl₃) according to the method of (Slimestad et al., 2007).

The results were expressed as mg quercetin equivalents/g sample of carob pods, fennel fruits, and rosemary leaves powder and their extracts.

HPLC analysis of phenolic and flavonoid components

The phenolic and flavonoid profile concentrations of fennel fruits, carob pods, and rosemary leaves were determined by HPLC according to the method described by (Mattila et al., 2000).

Experimental design of biological assays

Animal: The experiment is designed in the same way as (Reeves et al., 1993). One hundred and eight male albino rats were used in this study; fifty-four were used in model A, and the same number was used in model B, all of which were in a healthy state and weighed a starting weight of 100 ± 25 g. Rats were kept in conventional health laboratory settings for one week. The temperature was adjusted at $25 \text{ }^\circ\text{C} \pm 2$ and 12 h light-dark, and the rats were fed a basic diet and water ad libitum before the initiation of the experiment. All experimental methods were carried out at the Food Technology Research Institute, Agricultural Research Center, Giza, Egypt, in compliance with the Guide to the Care and Use of Laboratory Animals-NRC (2011) (NIH Publication No. 85-23, Revised 2011).

Induction of inflammation

Paw inflammation was caused in two separate ways. In the first model (A), a typical insulin syringe was used to administer 0.1 ml of formalin (2.5%) diluted in PBS (Sigma-Aldrich, Germany) subplantarily to the rat's right hind paw, causing edema. Before injecting formalin and after 1, 2, 3, and 4 hours, the paw thickness was assessed. By measuring the paw thickness with a calliper, the induced inflammation dose was measured. In the second model (B), 0.1 ml of 10% formalin was injected into the right hind paw of the rats in a manner identical to that described in the above-mentioned A model. Every day at a certain time for 15 days straight, a calliper was used to measure the thickness. Aqueous extracts and the standard medication were given orally via a gastric tube in the two experimental formalin models (A and B) 30 minutes

after the formalin injection in the right hind paw of the rat. However, in the second model (formalin 10%), treatments lasted for 15 days straight, while formalin was only administered on the first day. The formalin was made from a commercially available 37% formaldehyde solution, further diluted in isotonic saline.

$\% \text{ reduction of inflammation} = \frac{[(\text{paw thickness before treatment} - \text{paw thickness after treatment}) / \text{paw thickness before treatment}] \times 100}{100}$

Evaluation of *In Vivo* anti-inflammatory activity

A. 2.5 % formalin-induced paw edema model

The rats were randomly divided into nine groups, each containing six rats, as follows:

Group A1: normal control, with no induced inflammation. The rats were injected with 0.1 ml of the isotonic saline vehicle at the right hind paw.

Group A2: positive control group; received 2.5% formalin. Groups A3, A4: 2.5% formalin+ rats were administered fennel extracts at doses of 200 and 400 mg/kg rat b.w. Groups A, 5, and 6: 2.5% of formalin+ rats received carob extracts at doses of 400 and 800 mg/kg rat b.w. Groups A7, A8: 2.5% formalin+ rats treated with rosemary extracts at doses of 200 and 400 mg/kg rat b.w. Finally, group A9: 2.5% formalin+ rats were administered indomethacin 10 mg/kg as a standard curing drug.

B. 10% formalin-induced paw edema model

The animals received the same treatments as in the previous model, with the exception of group 2B, which received a 10% v/v freshly made formalin solution as an edema. Rats were administered 10% formalin plus the same extracts and standard medications for 15 days at the same doses.

Collection of blood and separation of serum

After the experimental period (15 days), the animal were fasted for 12 hours, anesthetized, and euthanized at the end of the treatment period; blood samples were obtained from the animal's ocular plexus under diethyl ether anesthesia. The samples were allowed to clot for 20 minutes at room temperature before being centrifuged for 10 minutes at

1006µg (3000 rpm) to separate the serum and utilize it for biochemical analysis. The biochemical parameters such as blood glucose (Trinder, 1969), serum protein, enzymatic antioxidants such as catalase (Aebi 1983), lipid peroxide (Ohkawa et al., 1979), and serum enzymes such as alanine transaminase, alkaline phosphatase, aspartate transaminase (King 1965), and creatine kinase (Okinaka et al., 1961 and Lowry et al., 1951). In whole blood, hematological parameters such as total leucocyte count, total red blood cells (RBC), total white blood cells (WBC), and hemoglobin were measured (Armour et al., 1965).

Histopathological Assessment

After the formalin-induced inflammation test and blood sample collection, the animals were sacrificed under inhaled ether anesthesia. The edematous skin was excised and fixed in 10% formalin-saline. It was processed and embedded in paraffin, yielding 5 µm-thick sections. Deparaffinized sections were stained with hematoxylin and eosin (H&E). The photomicrographs of each group were captured and interpreted for histopathological changes.

Statistical Analysis

The obtained data were subjected to a one-way ANOVA. SPSS statistical software (Version 10) was used for multiple comparison tests. Values

were expressed as means ±SE. A P value of ($p < 0.05$) was considered significant, according to (Snedecor and Cochran 1980).

3. Results and Discussion

Results

The results (Table 1.) demonstrated that the antioxidant activity, phenol content, and total flavonoid content of the examined materials all significantly increased after the extraction procedure. The radical scavenging value for fennel fruits (70%) was much greater than that of rosemary leaves (41.76%), and the lowest value was for carob (28.12%). Following extraction, the antioxidant activity of carob, fennel fruits, and rosemary all increased by a combined 85%, 14%, and 87%. The values of total phenols (mg of gallic acid/g of samples) in Table 1. showed, however, that fennel fruits had the highest values, followed by carob pods, while rosemary leaves had the lowest values. Following the water extraction of these herbs, the amounts of total phenols in the extract increased in carob, fennel, and rosemary by 137.5, 45.5, and 62.6%, respectively. Carob pods had the largest increase in total flavonoids, followed by fennel fruits, and then rosemary leaves. The amount of flavonoids overall greatly increased in the extracted rosemary (309.8%), whereas it decreased in the extracts of carob (63.35%) and fennel fruits (46.28%).

Table 1. Antioxidant activity, total flavonoid and phenolic contents of raw of fennel fruits, carob pods and rosemary leaves and their extracts

Sample	Antioxidant activity (%)	Total phenolic contents (mg of gallic acid/g of sample)	Total flavonoids contents (mg of quercetin/g of sample)
Fennel fruits	70.0 ^c ± 1.0125	42.0 ^c ± 1.245	3.5 ^e ± 1.0556
Fennel extract	80.0 ^a ± 0.986	61.1 ^a ± 0.896	5.12 ^b ± 0.8456
Carob pods	28.12 ^f ± 1.023	20.31 ^e ± 1.0456	3.82 ^d ± 1.0456
Carob extract	52.14 ^d ± 0.965	48.23 ^b ± 0.856	6.24 ^a ± 0.04356
Rosemary leaves	41.76 ^e ± 1.0456	15.45 ^f ± 1.0145	1.12 ^f ± 1.1456
Rosemary extracts	78.25 ^b ± 0.897	25.13 ^d ± 0.856	4.59 ^c ± 0.756

ANOVA used to compare data ($P \geq 0.05$); data sharing the same letter in a column were not significantly different.

Polyphenolic compounds, which are known to have antioxidant activity, Considerable concentrations of phenolic compounds were found in the aqueous extracts of rosemary leaves, fennel, and carob pods. These plants have significant amounts of carnosic

acid, carnosol, rosmarinic acid, and hesperidin in their polyphenolic profile. The effects of carob, fennel, and rosemary aqueous extracts on experimental rats with formalin-induced Table 2. lists the phenolic and flavonoid compounds found in the aqueous

extracts of fennel, carob, and rosemary. The aqueous extract of rosemary had the highest concentrations of chlorogenic acid, rosmarinic acid, and salvianic acid, and the lowest concentrations of ellagic acid and catechin compound. Thus, the carob extract saw an increase in its content of gallic acid (136 μ g/ml), caffeine (35.0 μ g/ml), propyl gallate (29.11 μ g/ml), catechin (21.6 μ g/ml), cinnamic acid (22.5 μ g/ml), and tannic acid (15.3 μ g/ml). Its content of ellagic acid (5.20 μ g/ml) and catechin (21.6 μ g/ml) is higher than that of rosemary and fennel extract. The amount of chlorogenic acid (250 μ g/

ml), rosmarinic acid (175 μ g/ml), cinnamic acid (25.61 μ g/ml), tannic acid (17.85 μ g/ml), and caffeic acid (16.1 μ g/ml) in the fennel extract increased. By separating the flavonoids, it was shown that the carob extract had a lower concentration of hesperidin, luteolin, apigenin, cirsimaritin, genkwanin, salvigenin, 7-CH₃-Rosmanol, carnosol, and 12-CH₃-carnosic acid compared to the fennel and rosemary extracts. Plants rich in phenols and flavonoids may therefore have significant anti-oxidant potential. Fennel extract (15.20 μ g/ml) and carob extract (8.10 μ g/ml) were both abundant in rutin.

Table 2. Polyphenolic and flavonoids fractions of fennel fruits, carob pod and rosemary aqueous extracts

Components	Fennel extract	Carob extract	Rosemary extract
Polyphenolic(μ g/ml)			
Gallic acid	0.89	136	2.60
Chlorogenic acid	250	2.03	215
Caffeine	1.23	35.0	0.92
Caffeic acid	16.10	12.10	5.40
Vanillic	6.02	3.40	2.45
Ferulic acid	5.65	0.02	0.11
Rosmarinic acid	175.0	0.15	207.5
Salvianic acid	21.51	9.0	19.25
Propyl gallate	0.95	29.11	1.45
Cinnamic acid	25.61	22.5	1.56
Tannic acid	17.85	15.30	0.05
Ellagic acid	0.87	5.20	0.02
Catechin	0.23	21.60	0.01
Flavonoids(μ g/ml)			
Rutin	15.20	8.10	0.01
Coumaric acid	0.05	2.51	0.02
Naringenin	0.15	6.10	0.01
myricetin,	0.02	13.20	0.01
Hesperidin	18.65	10.80	12.61
luteolin,	7.56	0.01	8.16
Apigenin	19.58	0.45	15.82
Cirsimaritin	18.65	0.07	15.20
Genkwanin	20.45	0.05	18.20
Salvigenin	5.69	0.045	9.56
Rosmadial	25.44	0.12	22.1
7-CH ₃ -Rosmanol	22.15	0.00	14.22
Carnosol	33.25	0.014	27.50
Carnosic acid	65.89	0.12	52.0
12-CH ₃ -carnosic acid	7.45	0.15	9.85

Inflammation were investigated in this study using two models (A and B). When 2.5% formalin was administered into rats in Model A for four hours, the aqueous extracts improved the volume of the paw and had an anti-inflammatory effect; however, they had no discernible effect on the outcomes of biochemical parameter testing. We conducted a 15-day experiment to examine the effects of extracts on inflammation (model B, 10% formalin). After 15 days, the histopathological and biochemical parameters of the extracts were evaluated favorably, and the extracts reduced inflammation when 10% formalin was injected. According to the findings of our investigation, indomethacin, fennel, carob, and rosemary extracts all impacted the tissue samples' ability to relieve swelling during formalin-induced acute inflammation. Results are presented as means with

standard errors. Rats' paw volume increased gradually over time due to the sub-planter injection of formalin (G2). In comparison to control rats (G1), the amount of paw volume increased by formalin was considerably reduced by fennel, carob, and rosemary extracts (Figures 1 and 2). In model A, study groups used treatment agents from one hour after a 2.5% formalin injection to four hours later (Figure 1). Following treatment, measurements carried out every one hour (1 to 4 hours) revealed that the rat's administration of 400 mg/kg Carob extract (G5) inhibited edema by approximately 35.66% (after 1 hr.) and 12.48%, respectively. However, after 15 days of treatment with 400 mg/kg of fennel extract in model B (10% formalin) group G4, there was a 19.88% suppression and inhibition of edema (Figure 2).

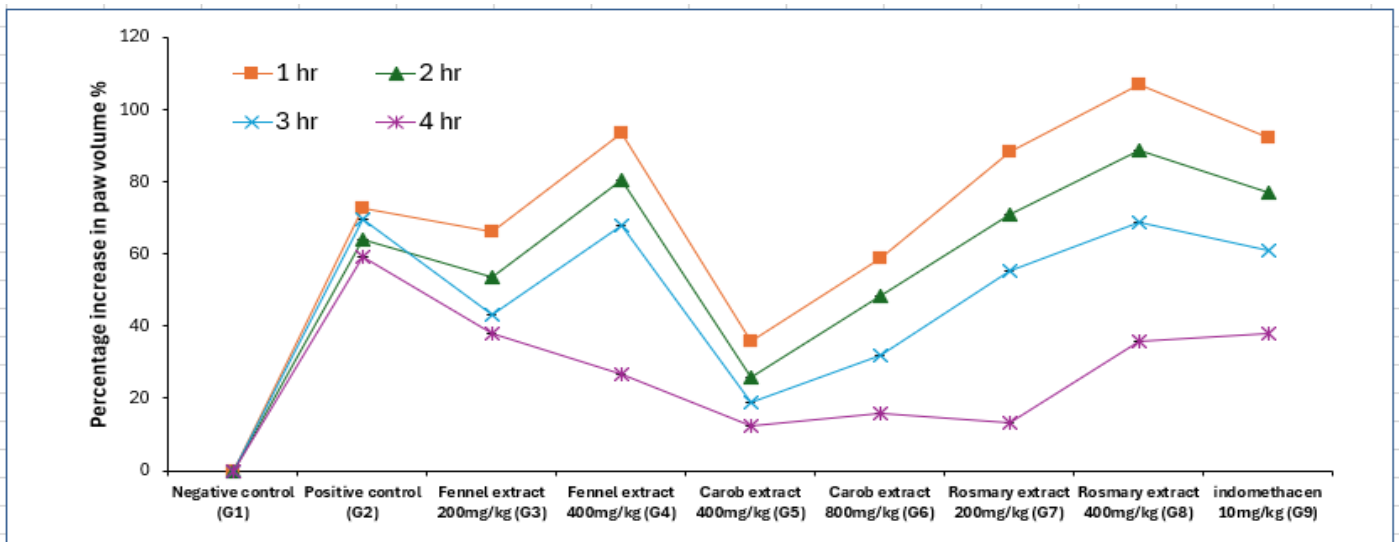


Figure 1. Paw edema induced by formalin in rats volumes in all groups according to time

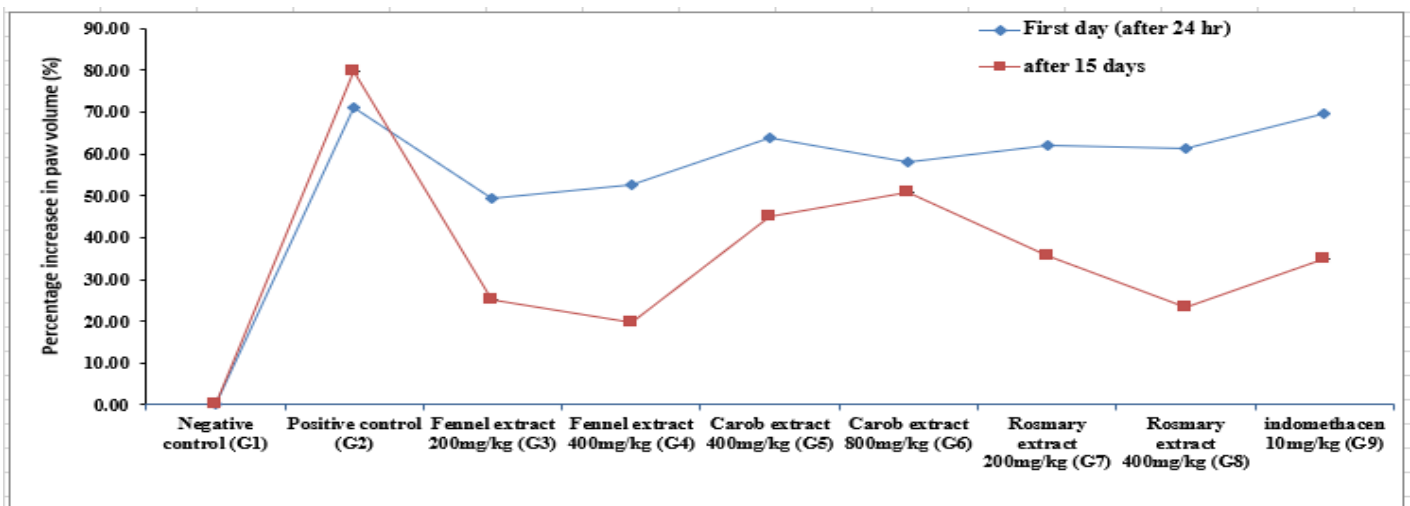
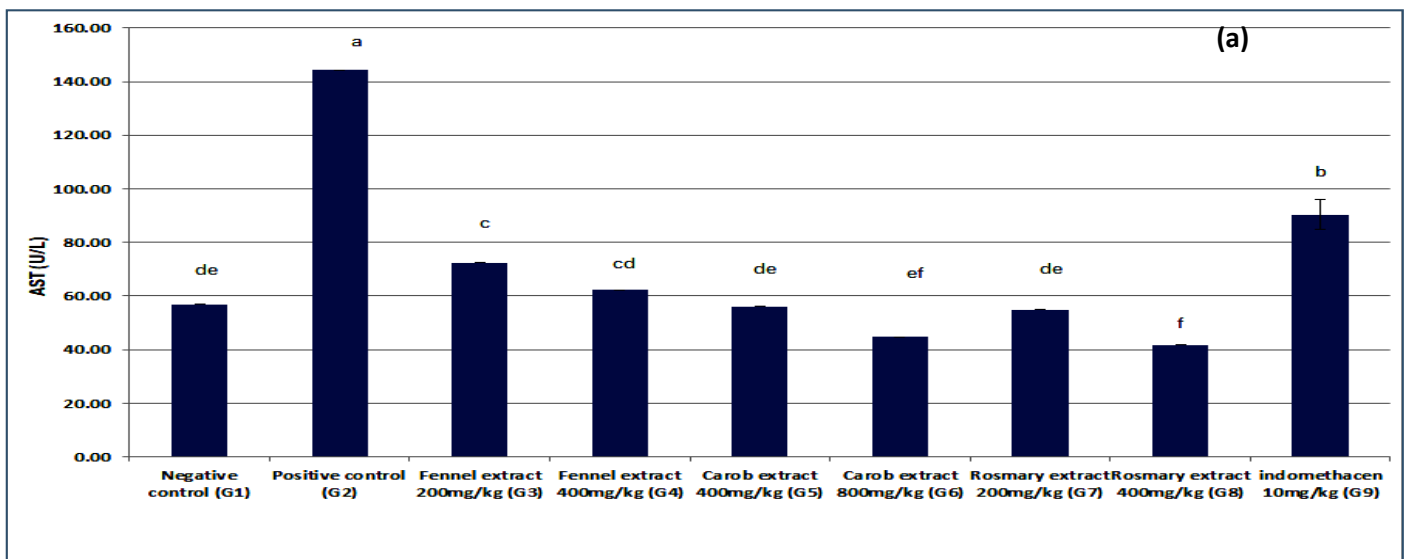


Figure 2. Paw edema induced by formalin in rats volumes in all groups according to time

The administration of 10% formalin to 15-day-old rats resulted in a substantial rise in liver enzymes, renal function, total WBC, blood glucose, and paw thickness, whereas these increases were prevented by the treatment with fennel, carob, rosemary extracts, and indomethacin. The inhibition of formalin-induced inflammation was dose-dependent with these administrations. Figure 3 (a–c) shows the effects of fennel, carob, rosemary extracts, and indomethacin supplementation on serum aspartate aminotransferase (AST), alanine aminotransferase (ALT), and alkaline phosphatase (ALP). enzymes are released into the bloodstream when the organs are harmed for whatever reason. Therefore, the concentrations of AST, ALT, and ALP in rat serum were examined. When compared to group 2, which had rats administered formalin 10% without any extracts or medications, the increase in AST was reduced by 71% and the increase in ALT by 72% in the rats given rosemary extract 400 mg/kg (G8).

On formalin-induced (10%) paw edema in rats, (Figure 3C) shows the mean levels of ALP enzymes for fennel, carob, rosemary extracts, and indomethacin compared to control (negative and positive). In the positive group (G2) of rats treated only with formalin, there was a highly significant increase in the ALP enzyme level ($p > 0.05$). Fennel, carob, and rosemary extracts all reduced ALP activity, according to the study. The enzyme levels in rats treated

with fennel extract at dosages of 200 and 400 mg/kg (G3 and G4) and rats treated with rosemary extract at doses of 200 and 400 mg/kg (G7 and G8) were not significantly different ($p > 0.05$). The percentages of decrease were 47.9%, 48.8%, 47.6%, and 48.5%, respectively. Furthermore, as compared to the control group (G1), there was a significant increase in urea and creatinine levels in rats treated with 10% formalin (G2) (Figure 4 a,b). In comparison to the positive group, fennel, carob, and rosemary extracts resulted in excellent restoration of urea and creatinine parameters (G2). The levels of lipid peroxide, catalase, and superoxide dismutase (SOD) were tested to see if fennel, carob, and rosemary extracts might prevent formalin-induced inflammation in a dose-dependent manner. When compared to the positive (G2), fennel, carob, and rosemary extracts increased CAT and SOD activity while decreasing lipid peroxide levels. As expected, the lipid peroxide levels in these extract-treated groups decreased, while CAT and SOD levels increased, indicating that these extracts have antioxidant properties. Fennel extracts 400 mg/kg (G4) and indomethacin 10 mg/kg (G9), on the other hand, inhibit lipid peroxide production even further. Carob extracts at 800 mg/kg (G6), rosemary extracts at 400 mg/kg (G8), and indomethacin at 10 mg/kg (G9) help boost SOD production. (Figure 5 a–c) displays the results.



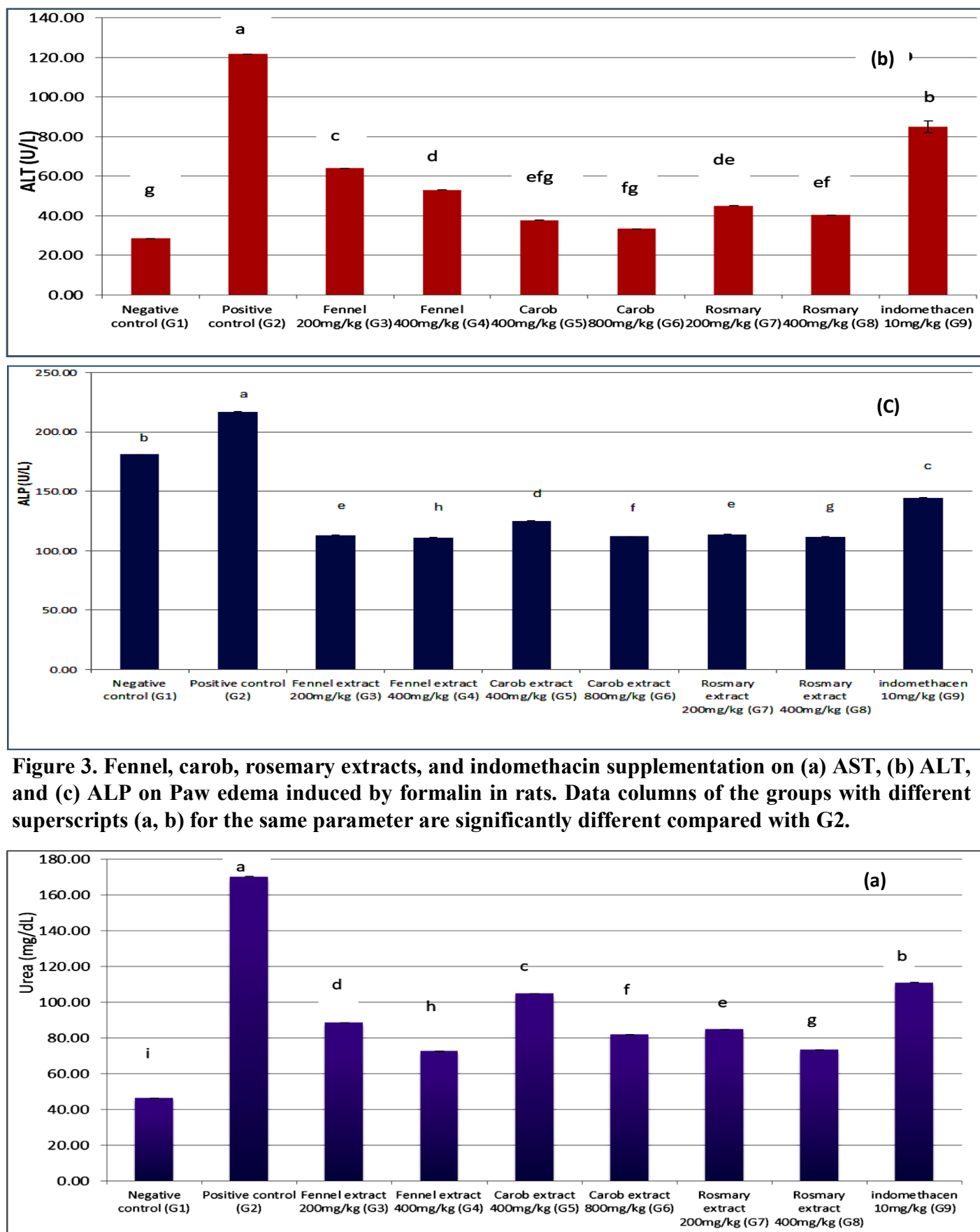


Figure 3. Fennel, carob, rosemary extracts, and indomethacin supplementation on (a) AST, (b) ALT, and (c) ALP on Paw edema induced by formalin in rats. Data columns of the groups with different superscripts (a, b) for the same parameter are significantly different compared with G2.

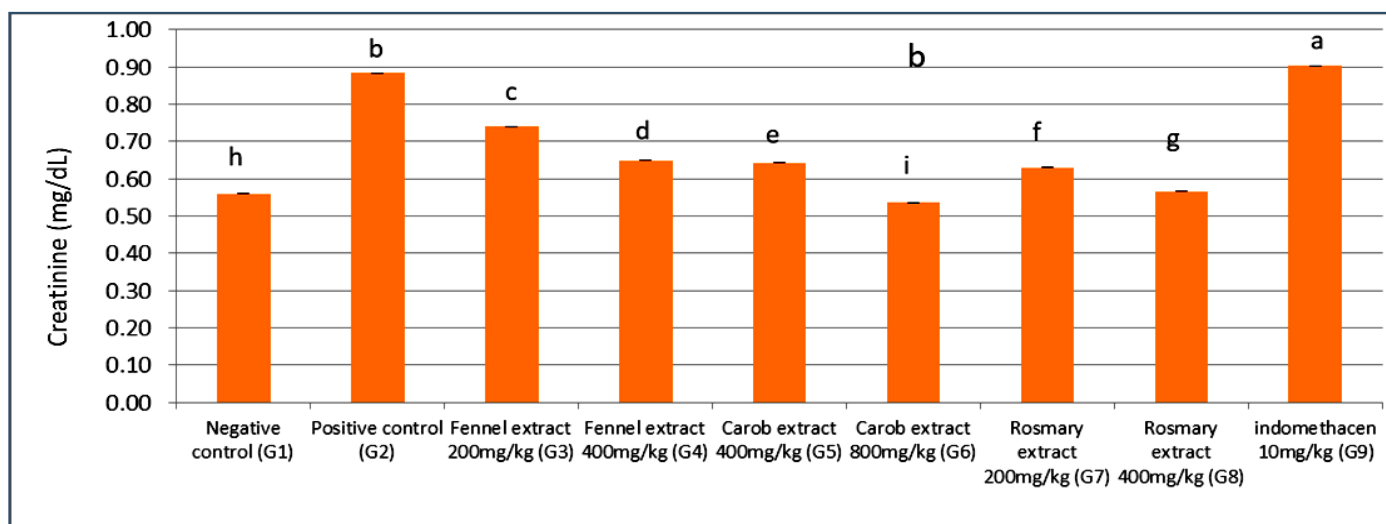
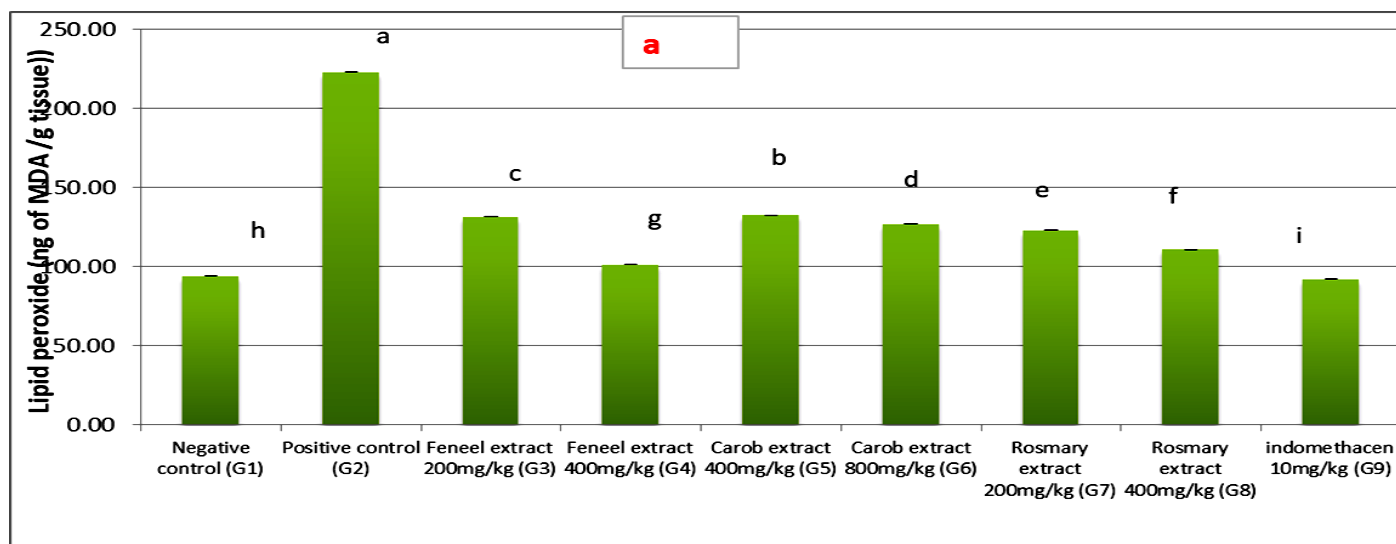


Figure 4. Fennel, carob, rosemary extracts, and indomethacin supplementation on serum (a) urea and (b) ceatinine levels on Paw edema induced by formalin in rats. Data columns of the groups with different superscripts (a,b) for the same parameter are significantly different compared with G2.

The levels of blood glucose in the positive control rats (G2) were 1.58-fold higher than in the negative group rats (G1), as seen in Fig. 6. When compared to the positive control, fennel, carob, and rosemary extracts, as well as indomethacin 10 mg/kg, effectively reduced formalin-induced rat paw edema ($P > 0.05$). (G2). It was also shown that there was no significant difference in the inhibition of formalin induced edema between the control group (G1), rats given fennel extract of 200, 400 mg/kg (G3, G4), rats given carob extract of 800 mg/kg (G6), and rats given rosemary extract of 200, 400 mg/kg (G7, G8). Tables 3 and 4 show the results of the effect of fennel, carob, rosemary extracts, and indomethacin on formalin-induced paw edema in rats on

hematological markers. In the positive group of formalin-induced rats (G2), hemoglobin and red cell count were significantly decreased ($p < 0.05$), whereas white cell count, neutrophils, lymphocytes, and eosinophils were significantly greater. In all of the treatments, hemoglobin and red cell count values were considerably higher ($p < 0.05$) than in the positive group (G2). Fennel, carob, and rosemary extracts, as well as indomethacin 10 mg/kg, cause a rise in hemoglobin and red cell count. When compared to the positive group (G2), there was a substantial drop in white blood cell count, neutrophils, lymphocytes, and eosinophils in seven treatments (G3 to G9).



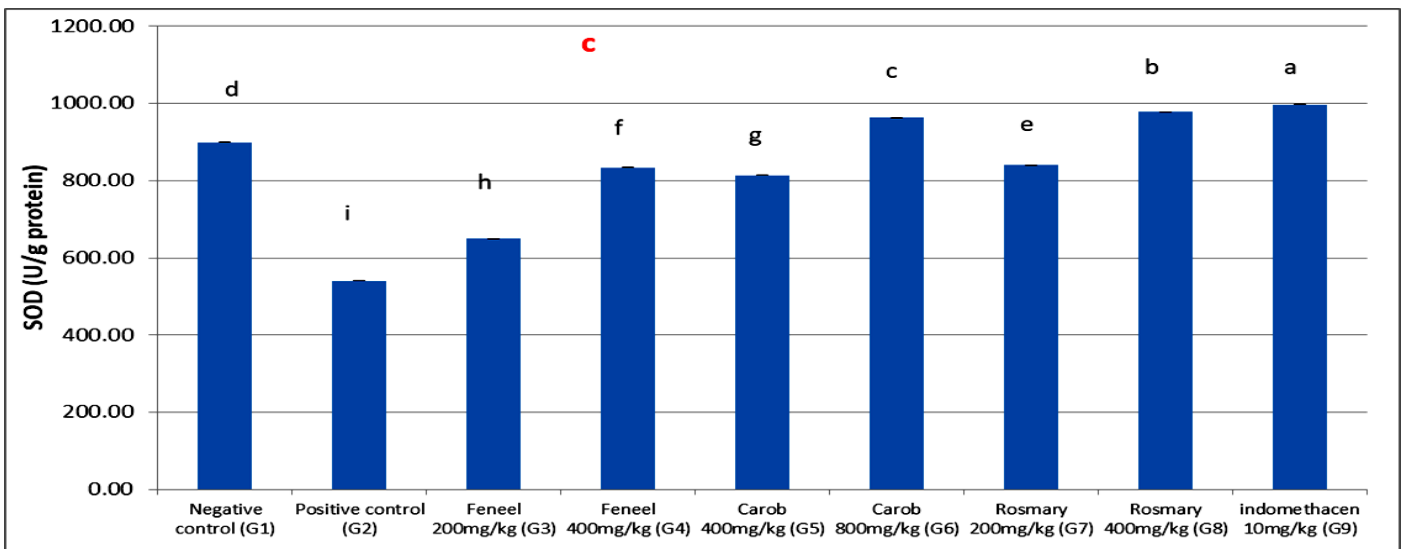
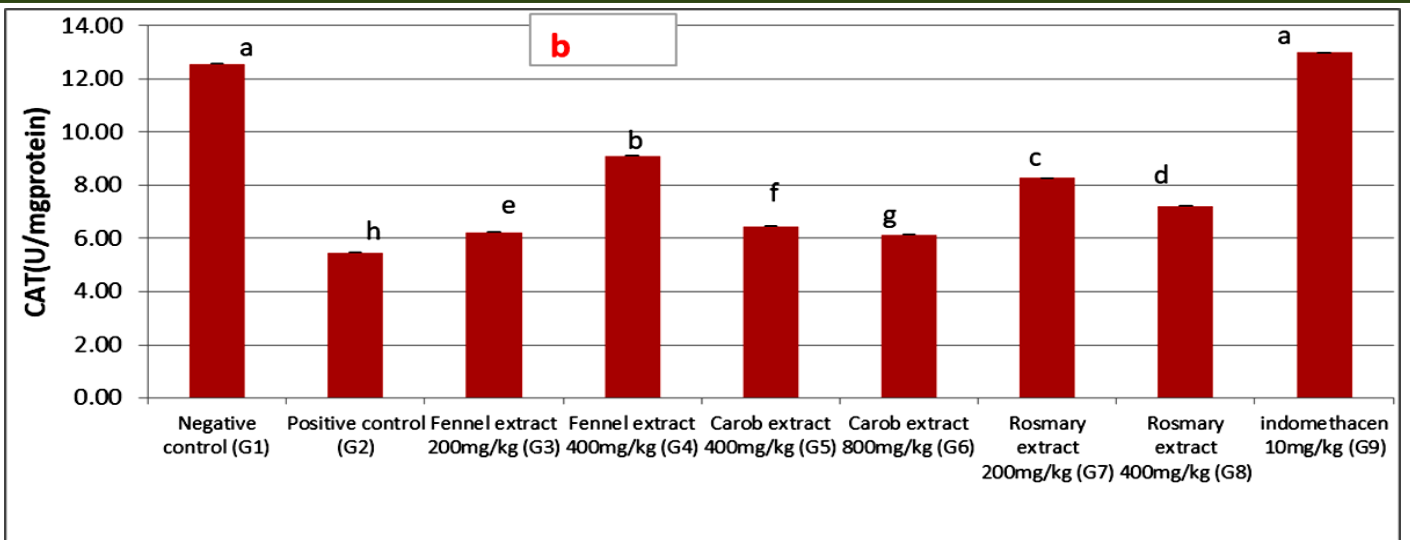


Figure 5. Fennel, carob, rosemary extracts, and indomethacin supplementation on (a) The levels of lipid peroxide, (b) CAT activity, and (c) SOD activity on Paw edema induced by formalin in rats. Data columns of the groups with different superscripts (a, b) for the same parameter are significantly different compared with G2.

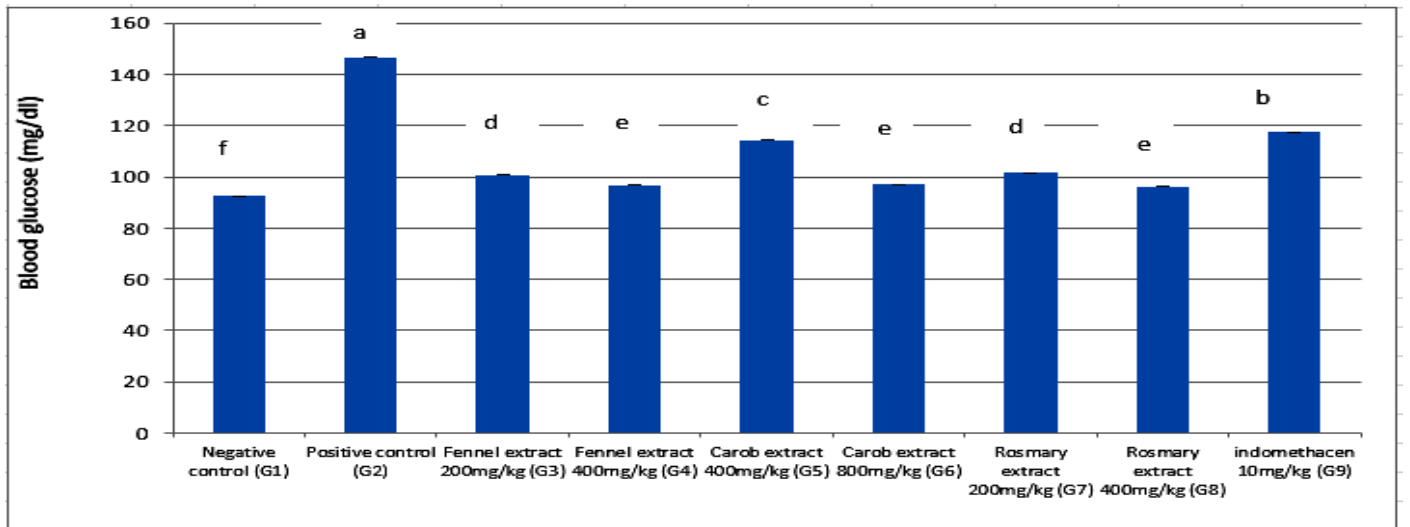


Figure 6. Fennel, carob, rosemary extracts, and indomethacin supplementation on The levels of blood glucose on Paw edema induced by formalin in rats. Data columns of the groups with different superscripts (a, b) for the same parameter are significantly different compared with G2.

Table 3. Levels of hemoglobin, red cell count, and white cell count

Groups	Haemoglobin (g/dL)	Red cell count (10^6 /uL)	White cell count (10^3 /cmm)
Negative control (G1)	10.73 ^d ±0.384	4.30 ^b ±0.265	8.66 ^e ±0.606
Positive control (G2)	7.66 ^e ±0.2403	2.43 ^c ±0.176	13.40 ^a ±0.360
Fennel extract 200mg/kg (G3)	13.00 ^b ±0.0577	4.96 ^{ab} ±0.088	11.23 ^b ±0.520
Fennel extract 400mg/kg (G4)	13.80 ^{ab} ±0.1732	4.63 ^{ab} ±0.348	10.76 ^c ±0.611
Carob extract 400mg/kg (G5)	12.30 ^c ±0.1732	4.86 ^{ab} ±0.233	9.80 ^d ±0.529
Carob extract 800mg/kg (G6)	13.60 ^{ab} ±0.4582	5.00 ^a ±0.264	8.80 ^e ±0.173
Rosemary extract 200mg/kg(G7)	13.40 ^{ab} ±0.1527	4.86 ^{ab} ±0.202	9.43 ^d ±0.166
Rosemary extract 400mg/kg(G8)	12.40 ^c ±0.2309	4.36 ^{ab} ±0.202	8.76 ^e ±0.348
Indomethacen 10mg/kg (G9)	14.20 ^a ±0.3605	5.09 ^a ±0.157	10.16 ^c ±0.272

Data are expressed as the mean ± SE, (n= 3 replicates). Means within the same column carrying different superscripts are significant different at $P \leq 0.05$

Table 4. Level of leucocytes in experimental rats

Group name	Neutrophils (%)	Lymphocytes (%)	Eosinophils (%)
Negative control (G1)	36.33 ^f ± 0.88192	17.90 ^f ±1.069	1.33 ^e ± 0.333
Positive control (G2)	74.76 ^a ± 2.61173	52.66 ^a ± 1.201	8.33 ^a ± 0.881
Fennel extract 200 mg/kg (G3)	34.00 ^g ±1.52753	41.00 ^c ± 0.577	4.50 ^c ± 0.288
Fennel extract 400 mg/kg (G4)	43.66 ^e ± 0.88192	39.00 ^d ± 0.577	2.83 ^c ± 0.440
Carob extract 400 mg/kg (G5)	43.00 ^e ±1.15470	43.33 ^b ± 0.881	4.56 ^b ± 0.536
Carob extract 800 mg/kg (G6)	43.00 ^e ± 2.08167	39.00 ^d ± 0.577	2.00 ^d ± 0.577
Rosemary extract 200 mg/kg (G7)	53.00 ^b ± 1.15470	40.33 ^{cd} ±0.881	4.33 ^b ± 0.333
Rosemary extract 400 mg/kg (G8)	52.00 ^c ± 1.73205	34.00 ^e ±1.154	2.00 ^d ± 0.577
indomethacen 10 mg/kg (G9)	49.00 ^d ± 0.57735	39.00 ^d ± 0.577	2.00 ^d ± 0.577

Data are expressed as the mean ± SE, (n= 3 replicates). Means within the same column carrying different superscripts are significant different at $P \leq 0.05$

The morphological alterations of the hind paw section skin tissue histology were evaluated by H&E staining to investigate the anti-inflammatory effects of fennel, carob, and rosemary extracts in experimentally induced paw edema with 10% formalin. As shown in Fig. 7, the hind paw section of the control group (G1) showed no discernible inflammatory cell infiltration, while the hind paw section of the rats treated with 10% formalin at a concentration of only (G2) showed massive inflammatory cell infil-

tration, dermal edema, and collagenous tissue proliferation. Nevertheless, administration of extracts from indomethacin, fennel, carob, and rosemary significantly alleviated the previously stated symptoms and reduced dermal edema and inflammatory cell infiltration. When rats were given Indomethacin (G9) at 10 mg/kg, a section of the skin on their hind paws significantly improved, but not as much as when fennel and rosemary (400 mg/kg) were given.

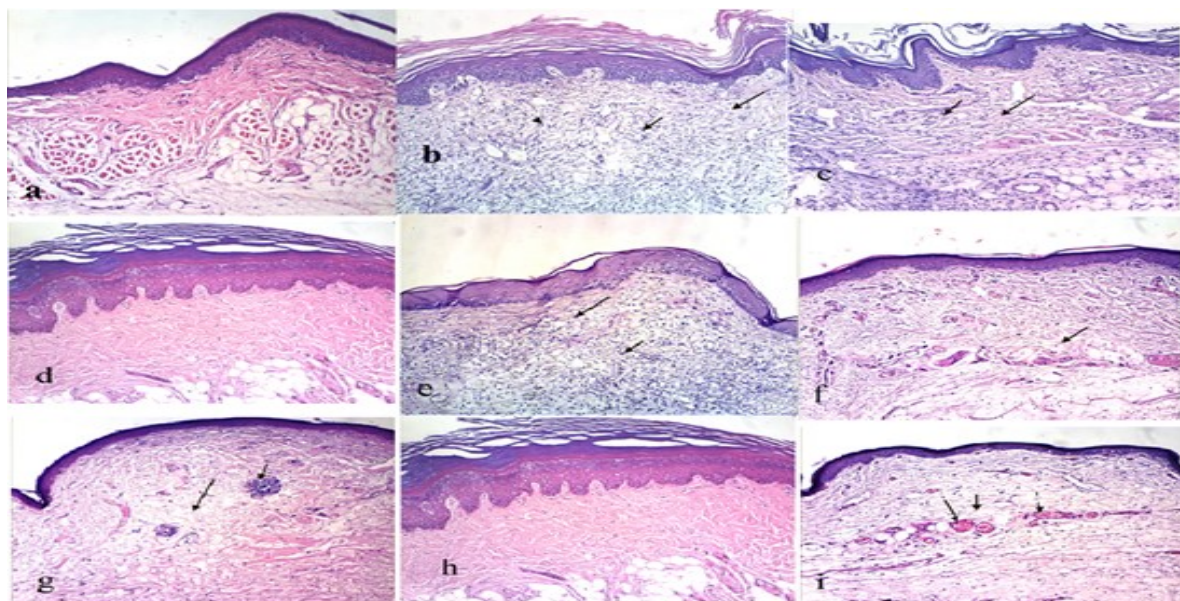


Figure 7. (a) Photomicrograph of the hind paw of rat from group 1 control negative showing the normal histology of hind paw from normal epidermis and dermis, (b) paw of rat from control positive group (G2) showing massive inflammatory cells infiltration and edema in the dermis as well as collagenous tissue proliferation, (c) paw of rat received fennel 200 mg/kg (G3) showing moderate inflammatory cells infiltration and edema in the dermis, (d) paw of rat received fennel 400mg/kg (G4) showing the normal histology of paw from normal epidermis and dermis, (e) paw of rat treated with Carob 400mg/kg (G5) showing moderate inflammatory cells infiltration and edema in the dermis, (f) paw of rat treated with carob 800mg/kg (G6) showing slight edema in the dermis, (g) paw of rat administrated with rosemary 200mg/kg (G7) showing small focal inflammatory cells aggregation in the dermis associated with edema, (h) paw of rat administrated with rosemary 400 mg/kg (G8) showing the normal histology of paw from normal epidermis and dermis, (i) paw of rat treated with indomethacin 10 mg/kg (G9) showing edema in the dermis and congestion of dermal blood vessels.

Discussion

In this study, the anti-inflammatory and antioxidant capacities of rosemary, carob, and fennel extracts were examined. Two models (2.5% formalin for 4 hours and 10% formalin for 15 days) were utilized in the formalin inflammatory method to evaluate the anti-inflammatory activity, while the DPPH photometric test was employed to evaluate the antioxidant activity. The phytochemicals phenol and flavonoid have potent anti-inflammatory actions (Peluso et al., 2013). According to a survey, phenolic compounds' antioxidant activity goes back to the impacts of their radical scavenging. In general, this procedure is preceded by a hydrogen atom or electron donation (Niki and Noguchi 2000). Numerous studies have demonstrated that rosemary extracts have potent antioxidant effects (Tironi et al., 2010). According to research by (Rohlik et al., 2013), several chemicals in rosemary, including rosmaridiphenol, rosmanolrosmariquinone, and carnosol, may exhibit antioxidant activity up to four

times that of BHA and be just as potent as butylated hydroxyl toluene. The components of carob pods, fennel fruits, and rosemary leaves' raw and their extracts' total phenolic and total flavonoid content were assessed and listed in Table 1. According to the study, the extracts can donate a proton, operate as scavengers or inhibitors of free radicals, and may even serve as primary antioxidants. These findings concur with those of Owen et al. (2003), who demonstrated the significant phenolic content of carob fiber. Additionally, carob fiber has a wide range of unique constituents from several classes, including simple phenolic acids, cinnamic acid and its derivatives, flavonoids, isoflavones, lignans, anthocyanins, and tannins. These substances therefore exhibit antioxidative, antimutagenic, anticarcinogenic, antiproliferative, or antioestrogenic effects when ingested regularly. According to Chatterjee et al. (2012), aqueous and methanol extracts of fennel fruits have significant phenolic contents and good antioxidant properties.

Anti-inflammatory activity is a characteristic of many flavonoids and of all phytoconstituents. Flavonoids have been found to have significant antioxidant, vasculoprotective, anti-hepatotoxic, anti-allergic, anti-inflammatory, and anti-tumor activity (Singh et al., 1989). Researchers discovered that the presence of phenolic chemicals, particularly flavonoids and diterpenes like carnosic acid and carnosol that are known for their antioxidant activity, is related to the bioactive qualities of rosemary (Achour et al., 2018). Traditional herbal medicines have grown in popularity globally in recent decades as a complement or alternative to conventional western medicine for both maintaining health and treating chronic, complex, or refractory conditions. One of the best test methods to assess chronic inflammation is formalin-induced paw edema, since it closely resembles human arthritis (Beg et al., 2011). As seen in Figures 1 and 2, treatment with aqueous extracts of fennel, carob, and rosemary reduced formalin-induced paw edema in a dose-dependent manner, exhibiting a significant anti-inflammatory effect for 15 days and 1 to 4 hours. The first thing that was noticed was a swollen paw following the injection of 2.5 and 10% formalin. After 15 days, rats fed 400 mg/kg of fennel (G4) and rosemary (G8) extracts showed the best anti-inflammatory activity. The proportion of inhibition increased over time. According to studies by (Ghasemzadeh Rahbardar et al., 2017 and Chatterjee et al., 2012), the polyphenolic chemicals in extracts of carob pods, fennel fruits, and rosemary are responsible for their functional properties, such as antioxidant and anti-inflammatory abilities. When administered as prescribed, indomethacin's various pharmacological anti-inflammatory effects on the rat paw inflammation test were most potent; however, after 15 days, the inhibition had decreased to 34.88%. Creating paw edema using formalin to mimic human arthritis is one of the finest ways to evaluate anti-arthritic and anti-inflammatory medications, particularly for long-term inflammation. In this model, neutrophils, macrophages, and fibroblast growth all contribute to the formation of edema (Ezeja et al., 2015). This is compatible with our findings. When formalin is

injected into a rat's paw, a biphasic response of the early neurogenic component and the later tissue-mediated response results in localized inflammation and pain (Beg et al., 2011). Localized inflammation and pain are produced when formalin is injected into a rat's paw. This reaction is biphasic, with the earlier neurogenic component followed by the later tissue-mediated response (Beg et al., 2011). Haematological and biochemical analyses of formalin-induced paw edema in the rats from the control group (G1) and the disease-treated (positive control) (G2) groups revealed a significant deviation from the normal range in the current study. According to the research, taking drugs or medical substances by mouth can change the normal range of hematological parameters (Ajagbonna et al., 1999 and Beg et al., 2011). Localized inflammation and pain are produced when formalin is injected into a rat's paw. This reaction is biphasic, with the earlier neurogenic component followed by the later tissue-mediated response (Beg et al., 2011). Haematological and biochemical analyses of formalin-induced paw edema in the rats from the control group (G1) and the disease-treated (positive control) (G2) groups revealed a significant deviation from the normal range in the current study. According to the research, taking drugs or medical substances by mouth can change the normal range of hematological parameters (Ajagbonna et al., 1999). Flavonoids and phenols have strong analgesic and anti-inflammatory effects, according to (Elizabeth et al., 2014). These may be the underlying factors behind the analgesic and anti-inflammatory benefits that fennel, carob, and rosemary extracts produced in the study participants. There is usually a connection between tissue damage, pain, and inflammation. The formalin test produces a biphasic reaction, with the first phase being the substance's immediate effects, which include neurogenic pain. The second phase is involved in the inflammatory reactions mediated by prostaglandin, serotonin, histamine, bradikinin, and cytokines such as interleukin-1 beta, interleukin-6, tumor necrosis factor-alpha eicosanoids, and nitric oxide (Fu et al. 2001).

The ability of non-steroidal anti-inflammatory drugs (NSAIDs) to inhibit the enzyme cyclooxygenase COX-1, which catalyzes the production of prostaglandins, is thought to be the cause of this negative effect. Prostaglandins produced by cyclooxygenase (COX-1) are crucial for maintaining the proper function of several organs, including the kidney, liver, and stomach, but those produced by COX-2 contribute to the onset of inflammation (Ng and Chan, 2010). This illustrates the effects of analgesics and anti-inflammatory drugs on the liver, kidneys, and stomach, among other organs. Therefore, we concluded that the active component of these plant extracts employed in this investigation did not inhibit COX-1 based on their anti-inflammatory effects without causing liver or kidney damage. The enzyme biomarkers AST, ALT, and ALP in the blood are used to monitor the liver's structural integrity and damage, as well as to help in the clinical diagnosis of liver toxicity (Simon-Giavarotti et al., 2002). Serum AST, ALT, and ALP activity are good indicators for diagnosing liver cellular abnormalities because they are abundantly released into the circulation following the breakdown of the hepatocellular membrane. (Al-Attar, 2011). In addition, ALT is detected only in the cytoplasm of hepatocytes, whereas AST is found in both the mitochondria and the cytosol. This study found that the formalin-induced rats had higher levels of ALT, AST, and ALP, suggesting liver impairment. This is in line with the data that has been presented by John and Shobana (2012). Hepatocyte transport function is disrupted after liver damage, leading to plasma membrane leakage (Pratt and Kaplan 2000), resulting in a rise in blood enzyme levels. The presence of increased AST and ALT levels in the blood indicates cellular leakage and a lack of cell membrane function in the liver, and they do provide information on the state of the liver (Thapa et al., 2015). As a result, it's possible that fennel, carob, and rosemary extracts are reducing the loss of cell membrane functional integrity in the liver in this investigation. The levels of AST and ALT were reduced after treatment with extracts at different dosage levels, and the synthesis of

physiologically active chemical mediators may have been influenced (Samadi-Noshahr et al., 2021 and Rocha et al., 2015). This study discovered that fennel, carob, and rosemary significantly reduce inflammation when compared to the anti-inflammatory medicine indomethacin but have no impact on the enzyme cyclooxygenase (COX-1)'s ability to produce prostaglandins. By reducing ALT and AST activity as well as urea and creatinine levels, they also maintain the health of the liver and kidneys. The extracts used in this study contain the flavonoids rutin, hesperidin, and apigenin, as well as the polyphenolic compounds gallic acid, chlorogenic acid, caffeic acid, rosmarinic acid, and tannic acid, which collectively inhibit cyclooxygenase (COX-2), which is responsible for inflammation by preventing the production of prostaglandins. Additionally, flavonoids and polyphenols are responsible for giving substances their functional properties, such as their ability to act as antioxidants and anti-inflammatory agents. These results are agreed with those from (Chatterjee et al., 2012; Elizabeth et al., 2014; Achour et al., 2018 and Ghasemzadeh Rahbardar et al., 2017). and polyphenols are responsible for giving substances their functional properties, such as their ability to act as antioxidants and anti-inflammatory agents. These results are in line with those from (Chatterjee et al., 2012; Elizabeth et al., 2014; Achour et al., 2018 and Ghasemzadeh Rahbardar et al., 2017). One of the most crucial mitochondrial antioxidant enzymes, SOD, defends cells from superoxide anions. Inflammatory conditions cause excessive phagocyte activation and the production of superoxide radicals, which can directly or indirectly damage nearby tissue. Examples include hydrogen peroxide and hydroxy radicals created from ROS, which cause LPO and membrane breakdown. The membrane breakdown leads to the creation of mediators and chemostatic chemicals, which set off an inflammatory response (Qiu et al., 2015). The current study also discovered a cumulative decrease in the levels of antioxidant enzymes and a considerable increase in the levels of lipid peroxide following the induction of formalin in experimental animals, both

of which are indicative of tissue damage. Treatment with fennel, carob, and rosemary extracts in various concentrations, on the other hand, restored antioxidant levels (SOD and CAT) and significantly reduced lipid peroxide levels. The activity of enzymatic antioxidants (SOD, CAT) significantly increased as a result of the study. As a result, the concentration of LPO in formalin-induced rats was shown to be greater in the current investigation. The LPO level was dramatically reduced after treatment with fennel, carob, and rosemary extracts at various dose levels. This is consistent with Akram et al. (2019) and El-Haskoury et al. (2018). According to Qiu et al. (2015), bone cells maintain a well-coordinated free radical scavenging system composed of antioxidants such as superoxide dismutase, catalase, glutathione peroxidase, and glutathione-S-transferase. Insulin makes it easier for glucose to enter cells. Another important chemical in the metabolism of carbohydrates is glucose. The body either synthesizes it through gluconeogenesis or digests complex carbohydrates to generate it (Panchal et al., 2013). According to the available evidence, formalin-treated rats exhibited noticeably increased serum glucose levels. Because formalin blocks glucose from entering cells, the investigation's findings indicated that the concentration of glucose in the serum increased. Our results are consistent with earlier research (John and Shobana, 2012) that examined the anti-inflammatory properties of a flavonoid molecule. Lymphocytes are the most prevalent cells in chronic inflammation. It has the potential to permanently change the tissue, causing it to stop working properly. Total white blood cells (WBCs) are a type of white blood cell that plays a critical role in the body's defense mechanisms. According to (Eric and Lawrence 1999), the release of interleukins, which are responsible for the formation of both granulocytes and macrophage colony stimulating factor, could be linked to an increase in WBC count during inflammation. As a result, in the current study, WBC counts were shown to be higher in formalin-induced inflammation. After oral therapy with fennel, carob, and rosemary extracts in various dosages, as well as indomethacen 10 mg/kg, the

WBC count was drastically lowered, showing impressive recovery from the inflammatory process. According to (Goel et al., 2001), leucocytes play a key role in the genesis and spread of inflammation. Neutrophils are the primary source of free radicals at the site of inflammation, and they are a manifestation of inflammation. Inflammation is known to be caused by neutrophil-derived free radicals, and neutrophil-produced cytokines are also responsible for inflammation. Eosinophils are leucocytes with granules that develop from stem cell progenitors. It produces and releases lipid-derived mediators that activate tissue responses. The oxygen transfer is aided by hemoglobin and red blood cells (RBCs). Anemia is caused by the induction of formalin, which produces a considerable drop in RBC and Hb levels. Treatment with fennel, carob, and rosemary extracts at various doses restored these levels to near-normal levels, which were comparable to the conventional drug-treated groups (indomethacen 10 mg/kg). Low Hb levels are seen in chronic inflammatory diseases such as rheumatoid arthritis, which is often accompanied by anorexia and weight loss. (Swingle and Shideman 1972) documented such a drop in Hb level.

In order to protect internal organs from infections and other noxious agents from the environment, the epidermis and dermis of the skin often exist in steady-state equilibrium. Layers of the skin that have been damaged set off intricate biochemical processes that result in tissue repair or normal healing. Inflammation, proliferation, and remodeling are the three phases that describe the process's dynamic and interactive occurrences. Under a light microscope, Group 1 (the negative control), which received normal saline, demonstrated normal skin tissue due to the normal epidermis and dermis, while Group 2 (the positive control), which received formalin (an inflammatory agent), demonstrated massive inflammatory cell infiltration and edema in the dermis as well as collagenous tissue proliferation.

This result is consistent with the study that was conducted by (Ali et al., 2013), Hyeong-Dong et al., 2010; Finbarrs Bello et al., 2020 and Rocha et al., 2015). This observed result demonstrates that there

is skin tissue inflammation. Groups 3 and 5 that took fennel and carob (200 and 400 mg/kg of extract) displayed mild dermal edema and infiltration of inflammatory cells. A slight amount of dermal edema was visible in the micrograph of group 6 after receiving carob (800 mg/kg of extract) treatment. Group 4 and Group 6 both displayed normal paw histology with normal epidermis and dermis when given the same amount of fennel and rosemary (400 mg/kg of extract). The experiment's findings demonstrated that the extracts in the current study significantly reduced the edema in the rat's paws in a dose-dependent manner. In the formalin-induced paw edema model B, the decrease was more evident at a dose of 400 mg/kg (fennel and rosemary). This shows that fennel, carob, and rosemary extracts may be beneficial at all concentrations in the neurogenic phase of inflammation. This implies that the extracts may have anti-proliferative properties and that greater doses are needed when using them to treat chronic inflammation. Several studies have indicated that the consumption of natural antioxidant compounds protects cells against the damage of reactive oxygen species such as singlet oxygen, superoxide, peroxy radicals, hydroxyl radicals, and peroxynitrite (Yang et al., 2013).

4. Conclusion

The results of the present investigation indicate that albino rats exposed to formalin undergo oxidative stress and inflammation. This is because the formalin process produces reactive oxygen species, which induce oxidative stress. Due to their anti-inflammatory and antioxidant properties, aqueous fennel fruits, carob pods, and rosemary leaves extracts prevent the formation of free radicals. Therefore, these extracts can be used to treat inflammatory diseases without endangering the liver or kidneys.

References

- Achour, M.; Mateos, R.; Ben Fredj, M.; Mtiraoui, A.; Bravo, L. and Saguem, S.A. (2018). Comprehensive Characterisation of Rosemary tea Obtained from *Rosmarinus officinalis* L. Collected in a sub-Humid Area of Tunisia. *Phytochem. Anal*, 29(1):87-100. DOI: 10.1002/pca.2717
- Aebi, H. (1983). *Catalase In: Methods in Enzymatic Analysis*, 3. New York: Ed Bergmeyer. H.U. Academic Press.
- Ajagbonna, O.P.; Onifade, K.I. and Suleiman, U. (1999). Hematological and Biochemical changes in rats given extract of *Calotropis procera*. *Sokoto Journal of Veterinary Sciences*, 1, 36–42.
- Akram, M.A.; Tembhre, M.; Jabeen, R.; Khalid, S.; Sheikh, M.A.; Jan, A. and Amin, M. (2019). Defensive role of *rosmarinus officinalis* in carbon tetrachloride-induced nephrotoxicity and oxidative stress in rats. *Bulletin of the National Research Centre*, 43(1). Doi:10.1186/s42269-019-0092-z
- Al-Attar, A.M. (2011). Hepatoprotective influence of vitamin C on thioacetamide-induced liver cirrhosis in wistar male rats. *Journal of Pharmacology & Toxicology*, 6(3):218–233. Doi:10.3923/jpt.2011.218.233
- Ali, A.H.; Behnam, G. and Mohammad, A.B. (2013). Potentiation of Indomethacin-Induced anti-Inflammatory response by montelukast in formalin-induced inflammation in rats. *Acta Medical Iranica*, 51(10): 675–680.
- Armour, D.F. E.; Blood, F.R. and Belden, D. (1965). *The Manual of Laboratory Work in Mammalian Physiology*. Liilious, Chicago: The University of Chicago Press., Liilious, Chicago pp. 4–6
- Bakirel, T. Bakirel, U.; Keles, O.S.; Igen, U. and Yardibi, H. (2008). "In Vivo assessment of anti-diabetic and antioxidant activities of rosemary (*Rosmarinus officinalis*) in alloxan-diabetic rabbits, *Journal of Ethnopharmacology*, 116, (1): 64–73.
- Barros, A.; Heleno, S.A.; Carvalho, A.M. and Ferreira, I.R. (2009). Systematic evaluation of the antioxidant potential of different parts of *Foeniculum vulgare* mill from Portugal. *Food Chem. Toxicol*; 47: 2458-2464.
- Beg, S., Swain, S.; Hassan, H.; Barkat, M.H. and Hussein, M.S. (2011). Systemic review of herbs as potential anti-inflammatory agents: Recent

- perspectives . *Pharmacogn. Rev*, (5): 120–137.
- Chatterjee, S Goswami, N. and Bhatnagar, P. (2012). Estimation of Phenolic Components and *in vitro* Antioxidant Activity of Fennel (*Foeniculum vulgare*) and Ajwain (*Trachyspermum ammi*) seeds. *Advances in Bioresearch*, 3 (2):109–118.
www.soeagra.com/abr/abr.htm
- Cheung, S. and Tai, J. (2007). Anti-proliferative and antioxidant properties of rosemary *Rosmarinus officinalis*, *Oncology Reports*, 17 (6): 1525–1531.
- Choie, E.M. and Hwang, J.K. (2004). Antiinflammatory, analgesic and antioxidant activities of the fruit of *Foeniculum vulgare*. *Fitoterapia*, 75 (6): 557–565.
Doi:10.1016/j.fitote.2004.05.005
- Cosge, B.; Kiralan, M. and Gurbuz B. (2008). Characteristics of fatty acids and essential oil from sweet fennel (*Foeniculum vulgare* Mill. var. dulce) and bitter fennel fruits (*F. vulgare* Mill. var. vulgare) growing in Turkey. *Natural Product Research.*, 22:1011-1016.
[Doi.org/10.1080/14786410801980675](https://doi.org/10.1080/14786410801980675)
- El-Haskoury, R.; Al-Waili, N.; Kamoun, Z.; Makni, M.; Al-Waili, H. and Lyoussi, B. (2018). Antioxidant activity and protective effect of carob honey in CCl₄-induced kidney and liver injury. *Archives of Medical Research*, 49(5): 306–313. Doi:10.1016/j.arcmed..09.011
- Elizabeth, A. A., Josephine, G., Muthiah, N. S. and Muniappan, M. (2014). Evaluation of analgesic and anti-inflammatory effect of *Foeniculum vulgare*. *Research Journal of Pharmacological, Biology Chemistry Science*, 5, 658–668.
- Eric, G. B. and Lawrence, J. (1996). Rheumatoid arthritis and its therapy, the Textbook of therapeutic drugs and disease management (6th ed. Williams & Wilkins Company, Eds.). *Baltimore*. 579–595. [[Google Scholar](#)]
- Ezeja, M.I.; Omeh, Y.N.; Onoja, S.O. and Ukaonu, I. H. (2015). Anti-inflammatory and antioxidant activities of the methanolic leaves extract of *Cissus aralioides*. *American Journal of Pharmaceutical Sciences*, 3(1):1–6.
Doi:10.12691/ajps-3-1-1
- Finbarrs, Bello, E.; IfeanachoEzeteonu, A. and Vincent, U. (2020). *In Vitro* therapeutic potential of leaves extract of *Eugenia uniflora* Linn on acute – inflammation rat model. *Journal of Diseases and Medicinal Plants*, 6(2): 31-38.
Doi:10.11648/j.jdmp.20200602.11
- Fu, K.Y., Light, A.R. and Maixner, W. (2001). Long-lasting inflammation and longterm hyperalgesia after subcutaneous formalin injection into the rat hindpaw. *The Journal of Pain*, 2(1): 2–11.
- Ghasemzadeh Rahbardar, M.; Amin, B.; Mehri, S.; Mirnajafi-Zadeh, S.J. and Hosseinzadeh, H. (2017). Anti-inflammatory effects of ethanolic extract of *Rosmarinus officinalis* L. and rosmarinic acid in a rat model of neuropathic pain. *Biomedecine & Pharmacotherapie [Biomedicine & Pharmacotherapy]*, 86,441–449. Doi:10.1016/j.biopha.2016.12.049
- Goel, R.K.; Sairam, K.; Rao, C.H. and Raman, V. (2001). Role of gastric antioxidant and anti *Helicobacter pylori* activities in the anti ulcerogenic activity of banana. *Indian J. Exp. Biol*, 39, 719–722.
- Goulas, V.; Stylos, E.; Chatziathanasiadou, M. V.; Mavromoustakos, T., and Tzakos, A.G. (2016). Functional components of carob fruit: Linking the chemical and biological space (Review). *International Journal of Molecular Sciences*, 17, 1875. 10-20.
Doi.org/10.3390/ijms17111875
- Guilled, M.D. and Manzanons, M.J. (1996). A study of severaparts the plant *Foeniculum vulgare* as a source of compounds with industrial interests. *Food Research International* ; 29, 85-88.
- Habtemariam, S. (2016). The therapeutic potential of rosemary (*Rosmarinus officinalis*) diterpenes for alzheimer’s disease. Hindawi Publishing Corporation Evidence-Based Complementary and Alternative Medicine Article ID 2680409, 14. Doi.org/10.1155/2016/2680409
- Hamidpour, R.; Hamidpour, S. and Elias, G. (2017). *Rosmarinus officinalis* (rosemary): A

- novel therapeutic agent for antioxidant, antimicrobial, anticancer, antidiabetic, antidepressant, neuroprotective, anti-inflammatory, and anti-obesity treatment. *Biomed of Journal Science Technology Research.*, 1(4): 1-6.
Doi: 10.26717/BJSTR.2017.01.000371
- Hyeong-Dong, K.; Kwang-Ho, C.; Byung-Wook, L.; Hyeong-Sik, K.; Seong-Hun, L. and Sae-Kwang, C. (2010). Effects of magnetic infrared laser irradiation on formalin-induced Chronic Paw Inflammation of Mice. *Journal of Physical. Therapy Science*, 22, 395–404.
- Iwu, M.M. ;Duncan, A.R. and Okunji, C.O. (1999). New antimicrobials of plant origin. In: Janick J. ed. *Prospective on new crops and new uses*. Alexandria, 457-462.
- John, N.A.A., and Shobana, G. (2012). Anti-inflammatory activity of *Talinum Fruticosum* L. On formalin induced paw edema in albino rats. *Journal of Applied Pharmaceutical Science*, 2 (1): 123–127.
- King, J. (1965). Transaminases: alanine and aspartate transaminases. *Practical Clinical Enzymology*. London: Van D. Nostrand Co. Doi:10.7326/0003-4819-64-2-4852
- Laura, P.F.; Garzon, M.T. and Vicente, M. (2010). Relationship between the antioxidant capacity and effect of rosemary (*Rosmarinus officinalis*L.) polyphenols on membrane phospholipid order. *Journal of Agricultural and Food Chemistry*, 58, (1):161–171.
- Lowry, O.H.; Rosebrough, N.J.; Farr, A.L.; and Randall, R. J. (1951). Protein measurement with the Folin phenol reagent. *The Journal of Biological Chemistry*, 193(1): 265–275.
Doi:10.1016/s0021-9258(19)52451-6
- Mattila, P.; Astola, J. and Kumpulainen, J. (2000). Determination of flavonoids in plant material by HPLC with diode-array and electro-array detections *Journal of Agricultural and Food Chemistry*, 48:5834-5841
- Maxwell, I.; Ezejal, Y.N.; Omeh, S.O.; Onoja, I. and Ukaonu, H. (2015). Anti-inflammatory and antioxidant activities of the methanolic leaves extract of *Cissusara lioides*. *American Journal of Pharmacological Sciences*, 3(1):1-6
- Ng, S.C. and Chan, F.K.L. (2010). NSAID-induced gastrointestinal and cardiovascular injury. *Current Opinion in Gastroenterology*, 26(6), 611–617. doi:10.1097/mog.0b013e32833e91eb
- Niki, E. and Noguchi, N. (2000). Evaluation of antioxidant capacity. What capacity is being measured by which method? *IUBMB Life*, 50: 323-329.
- Ohkawa, H.; Ohishi, N. and Yagi, K. (1979). Assay for lipid peroxides in animal tissues by thiobarbituric acid reaction. *Analytical Biochemistry*, 95(2): 351–358. Doi:10.1016/0003-2697(79)90738-3
- Okinaka, S.; Kumagai, H.; Ebashi, S.; Sugita, H.; Momoi, H.; Toyokura, Y. and Fujie, Y. (1961). Serum creatine phosphokinase. Activity in progressive muscular dystrophy and neuromuscular diseases. *Archives of Neurology*, 4: 520–525.
Doi.org/10.1001/archneur.1961.00450110050006
- Owen, R.W.; Haubner, R.; Hull, W.E.; Erben, G.; Spiegelhalder, B.; Bartsch, H. and Haber, B. (2003). Isolation and structure elucidation of the major individual polyphenols in carob fiber. *Food Chemistry of Toxicology*, 41: 1727-1738.
- Panchal, S.K.; Ward, L. and Brown, L. (2013). Ellagic acid attenuates high-carbohydrate, high-fat diet-induced metabolic syndrome in rats. *European Journal of Nutrition*, 52(2): 559–568. Doi:10.1007/s00394-012-0358-9
- Peluso, I.; Raguzzini, A. and Serafini, M. (2013). Effect of flavonoids on circulating levels of TNF- α and IL-6 in humans: a systematic review and meta-analysis. *Molecular Nutrition & Food Research.*, 57(5): 784–801.
Doi:10.1002/mnfr.201200721
- Pratt, D.S. and Kaplan, M.M. (2000). Evaluation of abnormal liver-enzyme results in asymptomatic patients. *The New England Journal of Medicine*, 342(17):1266–127
Doi:10.1056/NEJM 200004273421707
- Qiu, L.; Yin, G.; Cheng, L.; Fan, Y.; Xiao, W.; Yu, G.; Zhao, Y. (2015). Astragaloside IV ameliorates acute pancreatitis in rats by inhibiting the activation of nuclear factor- κ B. *International*

- Journal of Molecular Medicine, 35(3):625–636.
Doi:10.3892/ijmm.2015.2070
- Reeves, P.G.; Nielsen, F.H. and Fahey, G.C. (1993). AIN-93 purified diets for laboratory rodents: final report of the American Institute of Nutrition Ad Hoc Writing Committee on the reformulation of the AIN-76 rodent diet. *Journal of Nutrition* .,123:1939-1951.
- Rocha, J.; Eduardo-Figueira, M.; Barateiro, A.; Fernandes, A.; Brites, D.; Bronze, R. and Sepodes, B. (2015). Anti-inflammatory effect of rosmarinic acid and an extract of *Rosmarinus officinalis* in rat models of local and systemic inflammation. *Basic & Clinical Pharmacology & Toxicology*, 116(5):398–413. Doi:10.1111/bcpt.12335
- Rohlik, B.A., Pipek, P. and Panek, J. (2013). The effect of natural antioxidants on the color and lipid stability of Paprika salami. *Czech Journal of Food Sciences*, 31: 307–312.
- Samadi-Noshahr, Z.; Hadjzadeh, M.A.; Moradi-Marjaneh, R. and Khajavi-Rad, A. (2021). The hepatoprotective effects of fennel seeds extract and trans-anethole in streptozotocin-induced liver injury in rats. *Food Science & Nutrition*, 9 (2): 1121–1131. Doi:10.1002/fsn3.2090
- Simon-Giavarotti, K.A.; Giavarotti, L.; Gomes, L. F.; Lima, A.F. ;Veridiano, A.M.; Garcia, E.A. and Junqueira, V.B.C. (2002). Enhancement of lindane-induced liver oxidative stress and hepatotoxicity by thyroid hormone is reduced by gadolinium chloride. *Free Radical Research*, 36 (10):1033–1039. Doi:10.1080/1071576021000028280
- Singh, B.; Gambhir, S.S.; Pandey, V.B. and Joshi, V.K. (1989). Anti-inflammatory activity of *Echinops echinatus*. *Journal of Ethnopharmacology*., 25(2):189–199. Doi:10.1016/0378-8741(89)90021-4
- Singleton, V.L.; Orthofer, R. and Lamuela – Raventos, R.M. (1999). Analysis of total phenols and other oxidation substrates and antioxidants by mean of Folin-Ciocalteu reagent. *Methods In Enzymology*., 299, 152-178.
- Slimestad, R.; Fossen, T. and Vagen, I.M. (2007). Onions: A source of unique dietary flavonoids. *J Agric Food Chem.*; 55:10067-80.
- Snedecor, G.W. and Cochran, W.G. (1980). *Statistical methods Book*, p420, 7th Ed Iowa Stat Univ. Press, Ames, Iowa, USA.
- Sumathi, S., and Anuradha, R. (2018). Anti-inflammatory activity of dimethyl cardamonin on formalin induced paw edema in albino rats. *International Journal Biology of Medicine Research.*, 9 (2): 6338-6344.
- Swingle, K.F. and Shideman, F.E. (1972). Phases of the inflammatory response to subcutaneous implantation of a cotton pellet and their modification by certain anti-inflammatory agents. *The Journal of pharmacology and experimental therapeutics.*, 183(1): 226–234.
- Thaipong, K.; Boonprakoba, U.; Crosby, K.; Cisneros, L. and Byrnc, D.H. (2006). Comparison of ABTS, DPPH, FRAP, and ORAC assays for estimating antioxidant activity from guava fruit extracts. *J. Food Com. Anal.*,(19): 669-675.
- Thapa, B.R.; Goyal, R. and Kp, S. (2015). Interpretation of liver function tests. In *textbook of pediatric gastroenterology, Hepatology and Nutrition.*, chapter 21:294–294. Jaypee Brothers Medical Publishers (P) Ltd. Doi10.5005/jp/book/12548_22
- Tironi, V.A.; Tomas, M.C. and Anon, M.C. (2010). Quality loss during the frozen storage of sea salmon (*Pseudoperca semifasciata*). Effect of rosemary (*Rosmarinus officinalis* L.) extract. *LWT Food Science and Technology.*, (43): 363-372. Doi:10.1016/j.lwt.2009.07.007
- Trinder, P. (1969). Determination of glucose in blood using glucose oxidase with an alternative oxygen acceptor. *American Journal of Clinical Biochemistry.*, (6): 24 - 28.
- Yang, S.Y.; Hong, C.O.; Lee, G.P.; Kim, C.T. and Lee, K.W.(2013). The hepatoprotection of caffeic acid and rosmarinic acid, major compounds of *Perilla frutescens*, against-BHP-induced oxidative liver damage. *Food and Chemical Toxicology.*, 55: 92-99. DOI:10.1016/j.fct.2012.12.042.